

Innovations in the Treatment of Vaginal Prolapse

G. Willy Davila, MD, Coeditor

Section of Urogynecology and Reconstructive Pelvic Surgery
Department of Gynecology
Cleveland Clinic Florida
Weston, Florida

Robert D. Moore, DO, Coeditor

Director of Advanced Pelvic Surgery
Co-Director of Urogynecology
Atlanta Center for Laparoscopic Urogynecology
Alpharetta, Georgia

Thomas P. Giudice, MD

Associate Clinical Professor of Anatomy
University of South Carolina School of Medicine
Palmetto Health Baptist Hospital
South Carolina OB-GYN Associates
Columbia, South Carolina

Ty B. Erickson, MD

Chairman, Board of Managers
Mountain View Hospital
Chief Executive Officer
Rosemark WomenCare Specialists
Idaho Falls, Idaho

CONTENTS

Pelvic Organ Prolapse

THOMAS P. GIUDICE, MD.....2

Innovations in Surgical Approaches: Perigee™ and Apogee™ Placement Kits

TY B. ERICKSON, MD5

NEW TECHNOLOGY UPDATE

Innovations in Mesh and Graft Augmentation: IntePro™ and InteXen LP™

G. WILLY DAVILA, MD9

Tips and Pearls

ROBERT D. MOORE, DO.....11

APPENDIX I

Perigee™ Step-by-Step Procedure.....15

APPENDIX II

Apogee™ Step-by-Step Procedure.....16

Introduction

G. Willy Davila, MD, and Robert D. Moore, DO

Although approximately 30% to 50% of women are at risk for pelvic organ prolapse (POP) during their lifetime,¹ only 10% to 20% of these women seek medical treatment.² Most patients report that POP has a detrimental effect on their quality of life when they experience symptoms at least once per week.³ The goal of surgical treatment of POP is to relieve symptoms, achieve pelvic floor support, restore organ function, and treat and/or prevent sexual, bowel, or bladder dysfunction. Traditional surgery in all of these categories is often difficult, and failure can result in patient dissatisfaction. For example, a surgery may result in excellent support, but if the patient has pain with intercourse, the surgery cannot be considered a success. Unfortunately, with traditional procedures, 29% of patients require repeat surgery.⁴ With increasing medical advances, multiple surgical options are becoming available, and surgeons who perform pelvic floor reconstruction can tailor treatment in response to specific patient needs.¹

In this supplement, we review some of the newer surgical techniques and implant materials that are available for repair of POP. In the first section, Dr Thomas Giudice provides an overview of the relevant anatomic aspects of POP, followed by Dr Ty Erickson's comprehensive review of the innovative Perigee™ and Apogee™ procedures. The section on meshes and grafts by Dr G. Willy Davila provides surgeons with information and insight into the different graft materials that are available to help them make appropriate choices for their patients. The surgical tips and pearls section by Dr Robert Moore is a good resource for the beginner and a helpful review for the experienced surgeon who performs pelvic floor reconstruction.

DISCLOSURES

- **Dr Davila** reports that he receives grant/research support from and serves on the speakers' bureau of Adamed Inc., American Medical Systems, and Synovis Surgical Innovations and is a consultant to Adamed Inc. and American Medical Systems.
- **Dr Erickson** reports that he is a consultant to and serves on the speakers' bureau of American Medical Systems.
- **Dr Giudice** reports that he is a consultant to American Medical Systems.
- **Dr Moore** reports that he receives grant/research support from and serves as a consultant to American Medical Systems and is on the speakers' bureau of Esprit Pharma, Inc.

Images in this supplement courtesy of American Medical Systems.

THIS SUPPLEMENT TO OBG MANAGEMENT WAS SUPPORTED
BY A GRANT FROM AMERICAN MEDICAL SYSTEMS.

Pelvic Organ Prolapse

■ Thomas P. Giudice, MD

Pelvic organ prolapse (POP) is defined as the descent of a pelvic organ into or beyond the vagina, perineum, or anal canal.⁵ Although the majority of risk factors for POP (TABLE 1) occur before menopause, POP is most often seen in postmenopausal women in whom tissue atrophy and a loss of elasticity have further weakened pelvic support.⁶

Pelvic organ prolapse can localize in the anterior, posterior, or central pelvis and can cause lower urinary tract system, bowel, or sexual symptoms (TABLE 2).⁶ Anterior prolapse occurs when the urethra and/or bladder protrudes into the vagina. Posterior prolapse occurs when the rectum protrudes into the vagina, and vault prolapse occurs when the uterus or vaginal apex descends into the vagina. Although the specific location of prolapse may be identified, the entire pelvic floor must be considered a single entity during prolapse treatment (FIGURE 1).

Treatment of POP

Surgical treatment of POP is historically the most effective treatment. The goal is to relieve symptoms and restore vaginal anatomy, visceral function, and sexual quality of life. However, most surgical treatments to date have not provided adequate cure rates and/or anatomic outcomes. Traditional repairs have a failure rate that ranges between 25% and 52%.^{4,7-10} With increasing medical advances, multiple surgical options are becoming available. Pelvic floor reconstructive surgeons should be able to perform different procedures to tailor treatment to specific patient needs and pathologies.¹

Vault Prolapse: Traditional Options

The pelvic floor consists of the levator muscles and attached fascial tissues, which work in concert to support the pelvic organs. Deterioration of the supportive network that specifically involves the uterosacral-cardinal ligament complex can result in apical vault prolapse. Further descent of the vagina can compromise the lateral attachments of both the pubocervical and rectovaginal fasciae to the arcus tendineus fasciae pelvis, or white line. These

defects often coexist, with failure of the midurethral support culminating in urinary incontinence.

Traditional vaginal vault treatment options include McCall culdoplasty, uterosacral ligament suspension, ilio-coccygeus suspension, sacrospinous fixation, posterior intravaginal slingplasty vault suspension, and abdominal sacrocolpopexy.¹¹ These procedures are often technically difficult to perform and may change the vaginal axis,

TABLE 1

Risk factors for vaginal prolapse

- Parity, especially multiparity and complicated vaginal deliveries
- Previous prolapse surgery
- Hysterectomy
- Obesity
- Postmenopause
- Constipation or chronic straining during defecation
- Previous colposuspension
- Weak pelvic floor muscles
- Heavy lifting as occupation
- Large diameter of the bony pelvis
- Collagen abnormalities
- Decreased estrogen, especially associated with menopause

Mouritsen L. *Best Pract Res Clin Obstet Gynaecol.* 2005;19:895-911.⁶

TABLE 2

Symptoms associated with vaginal prolapse

Lower urinary tract symptoms

- Incontinence
- Voiding problems
- Nonspecific bladder-emptying problems

Bowel symptoms

- Constipation
- Fecal incontinence
- Obstructed defecation

Sexual symptoms

- Dyspareunia
- Sexual dysfunction
- Decreased sexual satisfaction

Mouritsen L. *Best Pract Res Clin Obstet Gynaecol.* 2005;19:895-911.⁶

thereby creating strain on previously weakened support tissues and predisposing the vaginal vault to additional support defects.

Anterior and Posterior Prolapse: Traditional Colporrhaphy

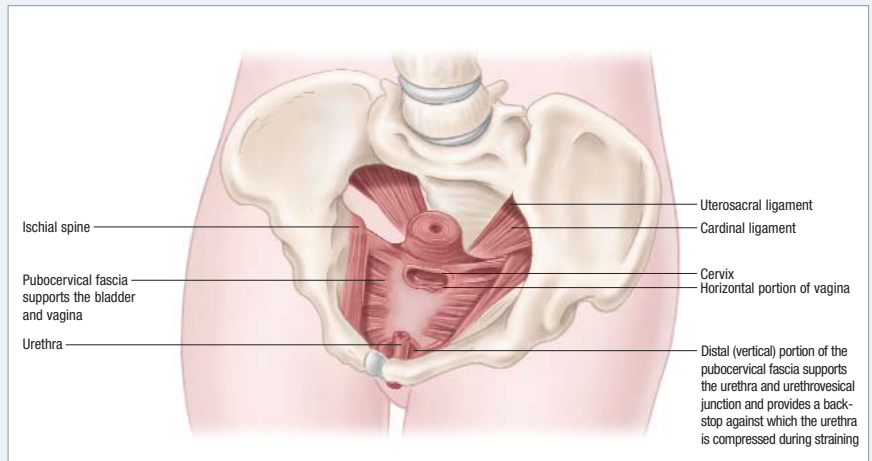
Anterior and posterior vaginal wall prolapse can be caused by midline, transverse, distal, and paravaginal defects. Traditional treatment consists of anterior and posterior colporrhaphy, during which the layers of the vaginal muscularis and adventitia overlying the viscera are plicated to reduce the protrusion. The etiology of anterior and posterior vaginal prolapse, although controversial, probably involves a combination of both disruption and attenuation of muscular and fascial tissues from their origin at the arcus tendineus along the pelvic sidewall. Histologic analyses of vaginal tissue have failed to identify a true fascial layer as classically described. (To help describe procedural technique, it is more appropriately considered a surgical layer.) It is this observation that likely explains the high failure rates with traditional colporrhaphy, while greater success is seen with paravaginal, site-specific, and graft-augmented repairs.

New Innovative Treatments

Although POP repair can be achieved through multiple routes, most surgeons agree that vaginal surgery offers less morbidity and pain and faster recovery than other approaches. These features often make surgical correction an option for patients not previously considered candidates for such procedures. Although the abdominal approach to vaginal repair has been associated with greater cure rates, it also carries increased morbidity and longer hospital stay and overall recovery time. The challenge becomes achieving the durability of the abdominal approach while preserving the minimally invasive nature of the vaginal approach.

FIGURE 1

Vaginal and uterine support structures



The upper pubocervical fascia supports the bladder, urethra, and vagina, and the lower rectovaginal fascia supports the rectum. Both the pubocervical and rectovaginal fasciae attach to the uterus, which in turn attaches to the uterosacral ligaments. Fascia provides continuous support from the opening of the vagina to the uterosacral ligaments.

TABLE 3

Comparison of selected surgical techniques for anterior prolapse repair

	Anterior Colporrhaphy	Anterior Colporrhaphy With Graft Augmentation [†]	Perigee™ [‡]
Procedure complexity	Low	Moderate	Moderate
Anesthesia	Regional	Regional	Regional
Operative time (min)	40	≤60	30
Potential complications	Bladder perforation Bleeding	Bladder perforation Pudendal nerve damage Bleeding	Bladder perforation Bleeding
Length of hospital stay (d)	1-2	1-2	≤1
Potential postoperative complications	Hematoma	Mesh erosion Extrusion Hematoma	Mesh erosion Extrusion Hematoma
Cure rate (%)	37-100*	90	>90

*Maher C, Baessler K. *Int Urogynecol J Pelvic Floor Dysfunct.* 2006;17:195-201.¹²

[†]Walters MD, Paraiso MFR. *Cleve Clin J Med.* 2005;72(suppl 4):S20-S27.¹³

[‡]Data on file. Protocol #MES052. American Medical Systems.¹⁴

Recent innovative approaches to vaginal wall repair use minimally invasive techniques to implant either polypropylene mesh or xenografts in a tension-free manner via the obturator foramen and/or the ischio-rectal fossa. Perigee™ (American Medical Systems, Minnetonka, Minn) is a standardized kit designed for comprehensive mesh or graft repair of anterior prolapse. The advantages of this kit include the ability to simultaneously repair multiple fascial defects (central, lateral, proximal, and distal) with a standardized, repeatable treatment, decreased operative time, and less postoperative patient morbidity (TABLE 3).^{12,13,14}

TABLE 4

Comparison of selected surgical techniques for vaginal vault and posterior wall prolapse repair

	Posterior IVS Tunneller™**	Sacrospinous Ligament Suspension*	Uterosacral Ligament Suspension*	Apogee™†	Sacral Colpopexy*
Procedure complexity	Low	High	Moderate to high	Low	High
Anesthesia	Local or regional	General or regional	General or regional	General or regional	General
Operative time (min)	15-20	120	120	35	120-240
Potential complications	Rectal perforation Mesh erosion	Pudendal nerve injury Pudendal/sacral vessel hemorrhage Vaginal deviation	Ureter injury Bladder perforation Rectal perforation	Mesh extrusion	Sacral hemorrhage Ureter injury
Length of hospital stay (d)	≤1	1-3	1-3	1	2-5
Postoperative pain regimen	May require PCA	May require PCA Buttock/leg pain	May require PCA	PCA followed by oral medication	May require PCA
Potential postoperative complications	Mesh erosion Mesh infection requiring removal	Stress incontinence Dyspareunia Cystocele	Suture erosion	Mesh extrusion Mesh erosion	Mesh erosion Mesh infection Stress incontinence
Cure rate (%)	91-94	73-98	80-100	92	95-100

IVS = intravaginal slingplasty; PCA = patient-controlled analgesia.

*Francis SL. *OBG Management*. 2004;16(suppl):S6-S11.¹⁵

†Data on file. Protocol #MES052. American Medical Systems.¹⁴

Similarly, the Apogee™ kit (American Medical Systems), available for the repair of vault and posterior wall prolapse, was designed to offer substantial improvements over traditional techniques (TABLE 4).^{14,15} For these repairs, a posterior vaginal and perianal approach is used to implant the mesh.

The mesh and graft materials available for use with

the Perigee and Apogee kits are designed to be self-fixating and to allow tissue ingrowth and integration by depositing new collagen to mimic the natural support system of the vagina and restore anatomic relationships. To date, more than 35,000 procedures using Perigee or Apogee have been performed worldwide with few complications. ■

Innovations in Surgical Approaches: Perigee™ and Apogee™ Placement Kits

■ Ty B. Erickson, MD

Traditional colporrhaphy techniques address only midline vaginal defects. These methods also involve the use of weakened tissue for support. Attaching poor-quality tissue to poor-quality tissue and placing it under increased tension probably contributes to the failure rate of nearly 30% observed with these techniques.⁴ Similarly, traditional vaginal vault suspension procedures can lead to vaginal shortening or an abnormal vaginal axis that may cause new prolapse to occur. An appropriately placed mesh or graft, however, has the potential to improve outcomes by recreating normal anatomy and circumventing some of the adverse events commonly seen with traditional techniques.

In the past, mesh or graft augmentation was used infrequently because it was perceived to require specialized surgical skills and extensive dissections that would result in increased patient morbidity, blood loss, and postoperative pain; increased risk of bladder or bowel perforation; and prolonged recovery. The lack of standardized mesh augmentation techniques may have contributed to this apprehension—more than 40 different operations for the treatment of vaginal vault prolapse have been described.¹

Perigee™ and Apogee™ are comprehensive, single-use needle suspension kits that provide a standardized delivery method for mesh- or graft-augmented repairs. Perigee uses the transobturator technique for the treatment of anterior prolapse; Apogee uses a posterior vaginal and perianal approach for the treatment of vault and posterior prolapse. These kits represent the “next generation” in vaginal prolapse repair because they allow for safe, consistent, comprehensive treatment and offer tension-free mesh- or graft-augmentation options to accommodate individual patient pathologies. They allow pelvic organ prolapse to be repaired in a minimally invasive manner with a short procedure time and a rapid postoperative recovery.

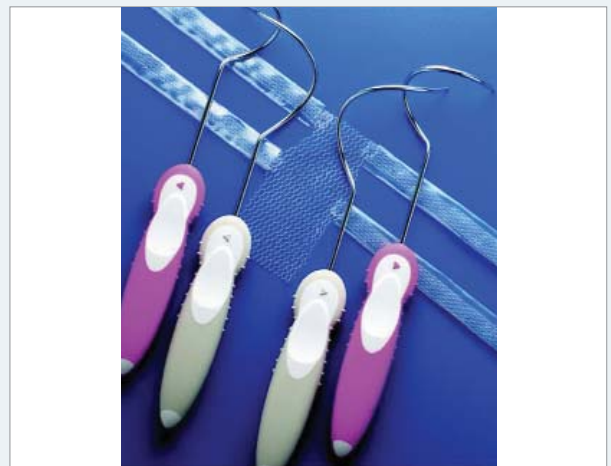
The Perigee kit contains 4 side-specific, patented, helical needles designed for each anatomic pass (FIGURE 2).

The kit includes a polypropylene mesh or porcine dermis graft that has 4 self-fixating, adjustable arms with special connectors to attach to the needles. The graft arms also feature a patented tensioning suture designed to maintain the integrity of the mesh arms as they are deployed through the anatomic passages.

In the transobturator approach, which is used with the Perigee system, helical needles are introduced from the groin through the obturator membrane into the lateral vagina to facilitate graft placement. The advantage of this approach is that it allows simultaneous treatment

FIGURE 2

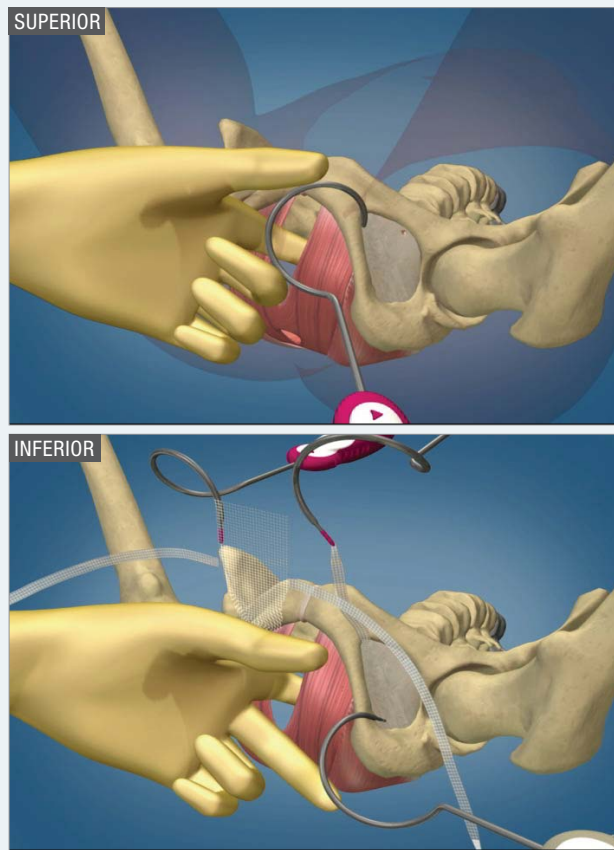
Perigee™ system for transobturator cystocele repair



This picture depicts the graft and needles used for anterior wall repair. The graft is 5 cm wide by 10 cm long. The apical portion of the graft has a tail that can be cut to fit the length of the patient's vagina. The graft has 4 arms extending laterally that are attached to the pelvic sidewall using needles passed through the transobturator space. The pink needles are the superior needles and are used to attach the bladder neck arms. The gray needles are the inferior needles and are used to attach the apical arms of the graft to the white line near each ischial spine. A large-pore polypropylene graft or a biologic porcine graft may be used.

FIGURE 3

Surgical technique for the Perigee™ kit



Very small incisions are made in the groin on each side. The superior incision is in the genitofemoral crease beneath the adductor longus tendon, and the inferior incision is 3 cm inferior and 2 cm lateral to this. The needle passes through the groin to enable connection of the anterior wall graft to the pelvic sidewalls.

bladder neck and directed cephalad toward the vaginal apex. (See Appendix I, *Perigee™ Step-by-Step Procedure*.) The surgeon then dissects the epithelium laterally, away from the bladder toward the ischial spine, similar to a traditional anterior repair. Two superior incisions are made (1 on each side) in the genitofemoral crease, lateral to the ischiopubic ramus, at the level of the clitoris; the smaller, pink helical needle is then passed through the obturator membrane and into the vaginal defect created by the prior dissection (FIGURE 3). The narrow diameter of the helix allows the needles to curve around the descending ischiopubic ramus with minimal risk of disrupting the neurovascular structures that traverse the obturator foramen. At this time, the needle can be palpated directly by the surgeon with a finger of the contralateral hand placed in the vaginal dissection, and the needle can then be guided to the exact location on the pelvic sidewall where the graft should be attached. The guiding finger also deflects the urethra and bladder away from the needle path, thus avoiding a “blind” needle passage and minimizing the risk of injury to both structures. The inferior incisions are made 3 cm below and 2 cm lateral to the superior incisions. The tips of the larger, gray needles are then brought through the inferior border of the obturator membrane and driven cephalad through the pelvis lateral to the levator muscles, perforating the white line near its attachment to the ischial spine (FIGURE 4). The arms of the mesh are attached to the needles with special connectors and are retrieved through their respective incisions. Once all needles are removed, the arms are used to adjust the mesh into place. The end result creates a hammock effect: the mesh under the bladder is attached laterally to the arcus tendineus fasciae pelvis, supporting the anterior compartment in the same anatomic position as the muscular and fascial components of the anterior compartment previously had done (FIGURE 5).

of multiple defects in the central, lateral, proximal, and distal anterior vaginal wall.¹³ Similarly, the Apogee kit facilitates the correction of rectocele, enterocele, and vault prolapse with one procedure.

Both the Perigee and Apogee kits can be used with a choice of mesh: either IntePro™ large-pore polypropylene mesh or InteXen LP™ lyophilized noncrosslinked porcine dermis graft. Both of these meshes have arms made of self-fixating polypropylene tape mesh for tension-free adjustment. The polypropylene tape mesh is designed to allow maximum fixation without mesh distortion and has been used successfully in the SPARC™ system (American Medical Systems) for nearly 5 years.

Repair Using the Perigee Kit

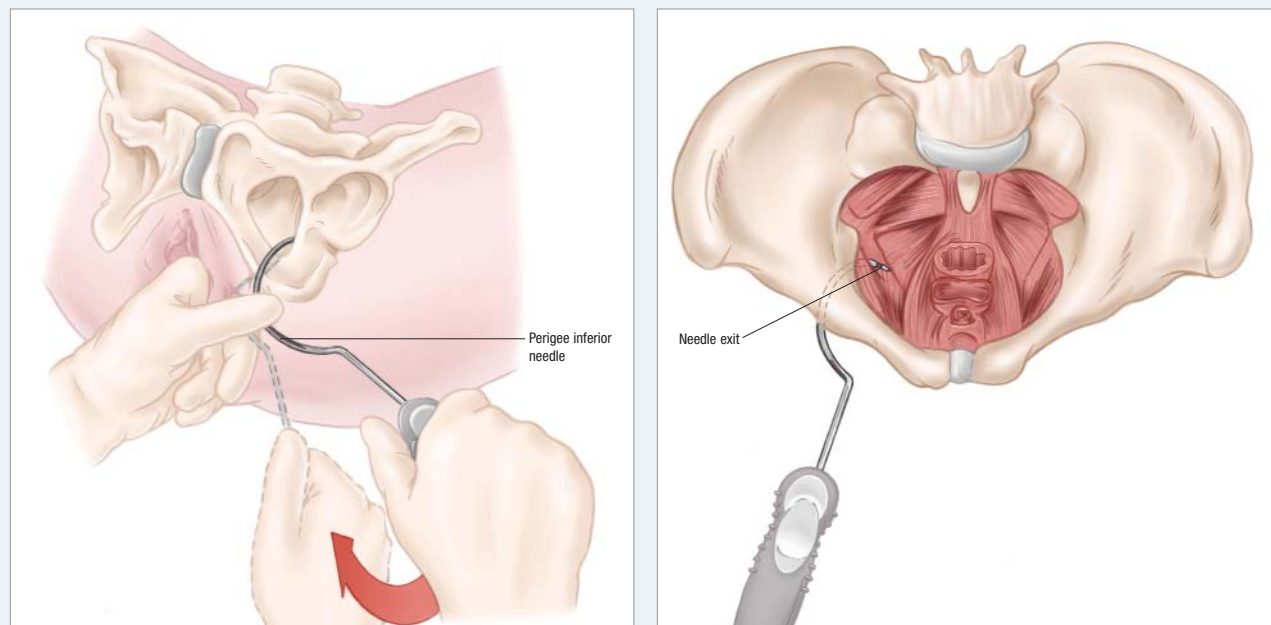
To perform a repair using the Perigee kit, a small vaginal incision is made in the midline, beginning at the

Repair Using the Apogee System

The Apogee system consists of 2 thin-profile curved needles and a mesh that has 2 self-fixating arms (FIGURE 6). (See Appendix II, *Apogee™ Step-by-Step Procedure*.) After making the vaginal dissection, which is similar to the dissection made for a traditional posterior repair, 2 small stab incisions are made 3 cm lateral and 3 cm posterior to the anus. The curved needles are then passed laterally via the ischiorectal fossa, parallel to the rectum (FIGURE 7). As the needle is passed through the ischiorectal fossa, the surgeon’s forefinger is used to palpate the needle tip below the levator muscles, and the middle finger is used to deflect the rectum medially.

FIGURE 4

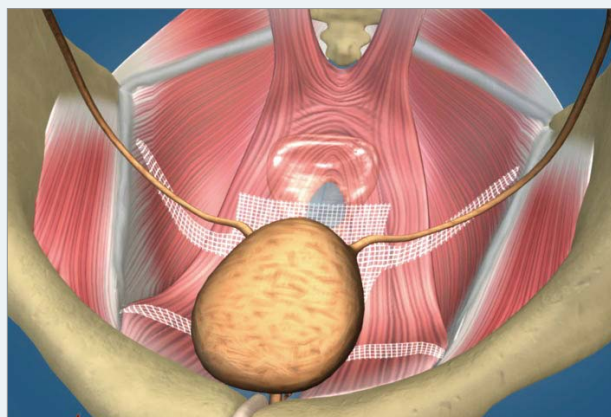
Perigee™ inferior needle passage



The Perigee inferior needle is passed through the inferior border of the obturator membrane and directed toward the ischial spine, exiting through the white line.

FIGURE 5


Final positioning of the Perigee™ system after reconstructive surgery to repair anterior vaginal prolapse



Once the needles are passed, the arms of the graft are attached to the needles and pulled out through the groin incisions. The arms are then adjusted and tightened, which moves the graft into place to support the bladder in its normal anatomic position. The tail of the graft is cut to fit the length of the patient's vagina and is attached to the pericervical ring (or vaginal cuff if the uterus is in place) using an absorbable suture before arm adjustment. The mesh graft forms a new layer of support under the bladder.

FIGURE 6

Apogee™ system for vaginal vault and posterior repair



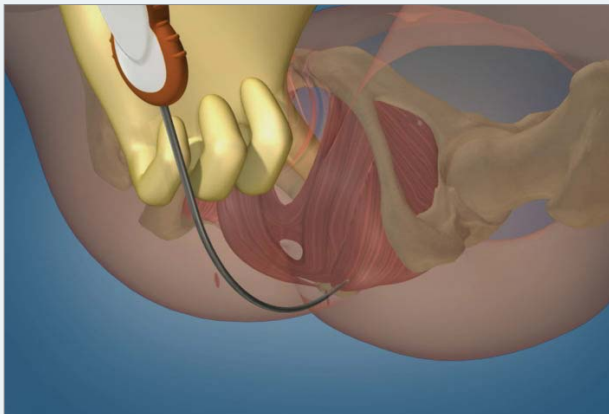
The Apogee kit includes 2 thin-profile, curved needles and 1 precut, large-pore polypropylene mesh graft, approximately 5 cm by 13 cm, with 2 mesh arms. The kit can also be used with a lyophilized porcine dermis graft. The Apogee kit enables surgeons to repair multiple defects with one ready-to-use, preconfigured system.

This technique limits blind passage of the needle and minimizes the risk of bowel perforation. The needle tip is delivered through the iliococcygeus, anterior to the ischial spine at the attachment of the cardinal ligaments, with direct palpation by the forefinger (FIGURE 8). The

arms of the mesh are attached, and the needles are withdrawn to fix the mesh in place. The arms of the mesh are positioned at the level of the ischial spines, which allows them to function as neoligaments analogous to the cardinal ligaments (FIGURE 9). Vaginal suspension at the level

FIGURE 7

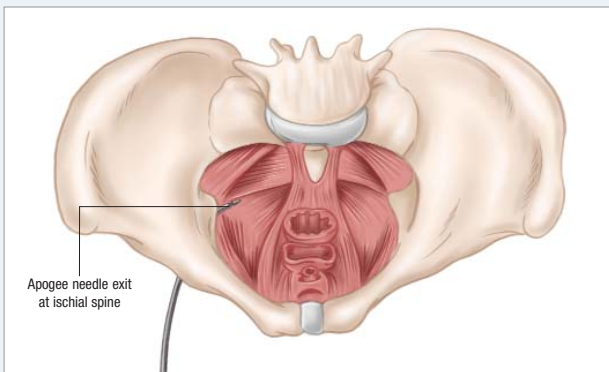
Surgical technique for the Apogee™ kit



Held in the 12 o'clock position, the needle should be inserted into the incision and passed through the ischioanal fossa.

FIGURE 8

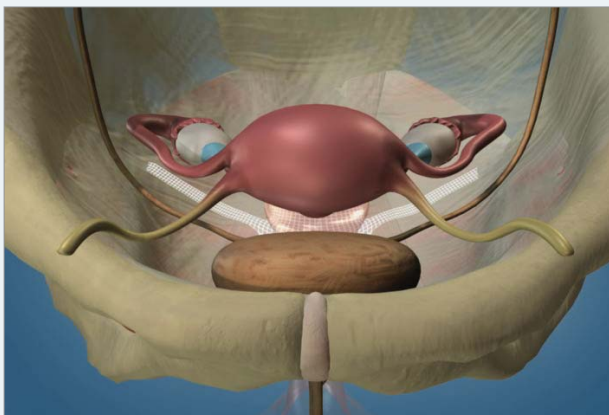
Apogee™ needle passage



The needle tip is delivered through the iliococcygeus, anterior to the ischial spine at the attachment of the cardinal ligaments, with direct palpation by the forefinger.

FIGURE 9

Final positioning of the Apogee™ system after reconstructive surgery to repair vaginal vault prolapse



of the ischial spine allows for a more physiologic vaginal axis while avoiding the neurovascular complications and postoperative occurrence of cystocele that are noted with traditional sacrospinous ligament fixation. The Apogee system allows for vaginal-approach techniques with increasing physiologic, anatomic, and functional outcomes that can provide successful level I support of the vaginal vault.

Total operative time for each of these procedures has been observed to be fairly short, making it feasible for either procedure to be performed in conjunction with other pelvic surgeries such as hysterectomy. In 1 pilot study of 11 patients, which was conducted by an experienced surgeon, the average operative time for the Perigee procedure was 18.4 minutes (range, 11 to 26 minutes).¹⁶ Short-term observations from multicenter trials have been very promising, and a retrospective study supports the initial success of the Perigee procedure.¹⁷

Adverse Events

Retrospective data gathered from a series of 299 cases at 15 clinical sites showed that, when performed by an experienced surgeon, the procedures had a cure rate of 92% and a uniformly low rate of adverse outcomes.¹⁸ The most common adverse events—extrusion and erosion of the mesh or graft into the vagina that require surgical intervention—occurred at a rate of 3.0%. Pain was reported as a complication of 3.3% of cases.¹⁴ No instances of surgical-site hematoma or infection, perirectal or perineal abscess, pelvic hematoma, or bowel perforation were reported in this series, nor were there any reports of erosion of the mesh into the viscera. Two instances of inadvertent cystotomy were reported.

Any new surgical procedure is associated with a learning curve for the surgeon, and an increased incidence of undesirable outcomes during this early learning period can usually be expected. However, further analysis of the Perigee and Apogee data showed that the incidence of adverse events was uniformly distributed throughout the time period of the study, and no initial spike in adverse events was observed, suggesting that these procedures can be mastered without a significant learning curve.

Physicians who are less familiar with the relevant pelvic anatomy or have limited experience with similar procedures would benefit from additional time and education, such as observing and practicing the procedure under the guidance of an experienced surgeon, working with cadavers and inanimate models, and being able to recognize and manage complications. ■

NEW TECHNOLOGY UPDATE

Innovations in Mesh and Graft Augmentation: IntePro™ and InteXen LP™

■ **G. Willy Davila, MD**

An inherent deficiency of traditional surgical repairs is the use of weakened tissue to support weakened tissue. Rather than truly repairing prolapse, such techniques often serve only as compensatory procedures because this suturing will be subjected to the same forces that caused the initial prolapse. Mesh or graft augmentation can correct paravaginal, anterior, or posterior compartment defects and restore anatomic support, which may decrease the rate of recurrence and the need for future surgeries.¹⁰ Material for augmentation can be a synthetic mesh or biologic graft, and physicians are encouraged to learn the benefits of each to tailor the choice of materials to the needs of individual patients. The Perigee™ and Apogee™ kits offer flexibility in choice of materials because they can be used with either a synthetic polypropylene mesh (IntePro™) or a lyophilized, noncrosslinked porcine dermis graft (InteXen LP™).

Synthetic Mesh: IntePro

Bioengineered mesh is readily available and is produced from a consistent manufacturing process, which offers reproducible elasticity, flexibility, and tensile strength. The width of the mesh weave must be large enough to allow macrophage infiltration, which prevents infection and promotes tissue ingrowth and collagen deposition. IntePro is a large-pore, monofilament, polypropylene type I mesh with an average pore size of more than 1000 microns, which enables macrophage infiltration (FIGURE 10).¹⁴ IntePro has proven effective in pelvic organ prolapse (POP) repair and has a recognized safety profile.

Compared with biologic grafts, synthetic mesh poses a higher risk for healing abnormalities such as extrusion. However, it is more appropriate for patients at high risk for recurrence from occupational or lifestyle factors and for patients undergoing concomitant procedures that may put the mesh under additional strain. In

a retrospective chart review of 299 patients who underwent POP repair with IntePro and Apogee, Perigee, or a combination of these kits, 3% of patients experienced mesh extrusion into the vagina that required surgical intervention. Another 7% experienced extrusion that was managed with minimal intervention, such as applying topical estrogen or trimming the IntePro mesh in an outpatient setting.¹⁴


Biologic Grafts: InteXen LP

As a class, biologic grafts present less risk of healing abnormalities than synthetic meshes. Biologic grafts are ideal for a diverse range of patients: those with poor tissue quality, for example, in cases of radiation therapy, patients for whom tissue extrusion/erosion is a heightened concern due to vaginal atrophy, and women who are undergoing concomitant vaginal hysterectomy.

InteXen LP is a noncrosslinked porcine dermis graft that facilitates tissue ingrowth to repair and maintain collagen integrity in vivo. InteXen LP materials are

FIGURE 10

IntePro™ is a large-pore soft polypropylene type I mesh with an average pore size of >1000 microns



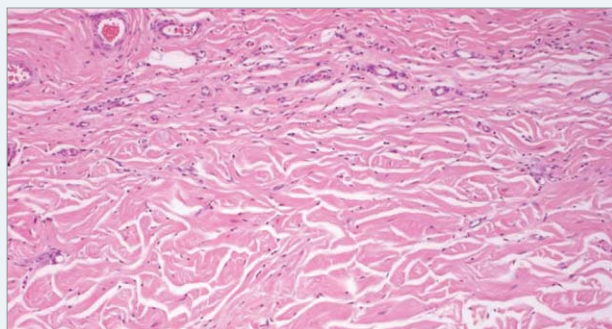
The mesh is monofilament and designed to allow complete macrophage infiltration, thus greatly reducing risk of infection. If infection occurs, the mesh does not usually need to be removed.

TABLE 5
Comparison of crosslinked and noncrosslinked biologic graft materials

Crosslinked*†	Noncrosslinked‡
• Stabilizes bonds between molecules	• Simple acellular sheet of biologic material
• Prevents collagen ingrowth	• Recreates natural support mechanism
• May shrink	• Amenable to collagen ingrowth
• Unknown long-term data	• Integrates with endogenous collagen
• Risk of encapsulation	• Enables revascularization
	• No risk of encapsulation

*Gandhi S, et al. *Am J Obstet Gynecol.* 2005;192:1643-1648.¹⁹
 †Davila GW. *Cleve Clin J Med.* 2005;72(suppl 4):S28-S32.²⁰
 ‡Data on file. Internal test report 3135. American Medical Systems.²¹

FIGURE 11
InteXen LP™ is noncrosslinked porcine dermis



The graft facilitates tissue ingrowth and maintains collagen integrity (pink), thus strengthening repair. Tissue ingrowth (purple) is shown here as prolific capillary formation.²¹

TABLE 6
Patient subsets effectively treated with synthetic or biologic surgical augmentation of pelvic organ prolapse repair

Synthetic Meshes Best for patients who:	Biologic Grafts Best for patients who:
• Need permanence and strength	• Require reinforcement of endogenous tissue
• Have had failure with traditional surgical options	• Have atrophic vaginal tissue
• Show evidence of tissue under strain	• Have had radiation
• Experience chronic cough	• Have suspected healing difficulty that may lead to recurrence
• Perform heavy lifting	• Are sexually active
	• Are undergoing concomitant vaginal hysterectomy

processed with effective viral and prion inactivation steps, and to date no disease transmission has been observed. In 1 retrospective chart review, InteXen LP

demonstrated effectiveness in vaginal POP repair using the Perigee or Apogee kits, or both. The overall cure rate was 91% (G.W.D., unpublished data, 2006). Of the 63 patients in this study, 15.9% reported an adverse event (10 patients), including urinary tract infections, pain, wound dehiscence, wound infection, anemia, incomplete healing of the surgical incision, treatment failure after violent vomiting, and lower urinary tract symptoms of urgency, frequency, and/or nocturia.¹⁴ Notably, no extrusions or erosions were reported in the InteXen LP group nor were there any reports of de novo incontinence or dyspareunia.

A key benefit of InteXen LP over other biologic grafts is that it is noncrosslinked. (A comparison of crosslinked and noncrosslinked biologic graft materials appears in **TABLE 5**.¹⁹⁻²¹) Crosslinked material prevents collagen ingrowth and can result in encapsulation. InteXen LP supports collagen ingrowth so that the graft is incorporated as endogenous tissue, allows the revascularization necessary for proper wound healing and immune function, and does not lead to encapsulation (**FIGURE 11**).

Both synthetic and biologic materials offer significant benefits over traditional repair without augmentation.⁹ As with any surgical procedure, there are risks associated with these technologies but, for the most part, the risks have been relatively small and limited to the introduction of foreign material and the potential for extrusion or erosion complications. Other risks include bleeding, pain in the vagina or groin, vaginal scarring, and pain with intercourse. However, recent advances in mesh/graft implantation allow for less invasive and simpler procedures that require less dissection and suturing, thereby decreasing blood loss, operative time, and recovery time. These advances may potentially improve the long-term solutions for POP repair.

Traditionally, mesh or graft augmentation has been reserved as a second-line surgical treatment for patients for whom traditional surgical treatment has failed. Today, however, augmentation recommendations have expanded, extending to patients receiving radiation treatment, sexually active patients, and patients undergoing concomitant vaginal hysterectomy and other procedures that place the grafts under strain (**TABLE 6**). The extended indications for graft augmentation are in part the result of improved mesh/graft technology and the expanded options inherent in offering surgeons a choice of implant material. The Apogee and Perigee kits offer surgeons flexibility and discretion in material choice, allowing for more comprehensive treatment options for POP repair. ■

Tips and Pearls

■ Robert D. Moore, DO

Even when surgeons are appropriately trained in vaginal prolapse repair, perioperative complications can still threaten the outcome and durability of reconstructive procedures. The majority of these complications are within the surgeon's control and, therefore, should be kept in mind during surgical planning and postoperative care. This section details some preoperative, intraoperative, and postoperative techniques to prevent healing difficulties. It also offers some practical tips for performing mesh- or graft-augmented vaginal prolapse repair, gleaned from the experience of the early adopters of this procedure.

Anatomic Landmarks

Before performing any pelvic reconstructive surgery, the surgeon should be familiar with the anatomic landmarks that will be used for guidance during the procedure. Most of these landmarks can be found by palpation. The bony landmark of most importance during procedures with the Perigee™ and Apogee™ kits is the ischial spine, as this is the point of origin of both the sacrospinous ligament and the arcus tendineus, or the white line. The goal is to obtain passage through the iliococcygeus and white line as close to the ischial spine as possible to achieve the best apical support. (See *Appendices I & II for step-by-step procedures using the Perigee and Apogee kits.*) The Apogee needle should not be driven past the ischial spine or through the sacrospinous ligament, as this will risk injury to the pudendal nerve or vessels. The helical Perigee needle was designed to protect against such injury by preventing the surgeon from driving the needle in too deeply. The ischial spine can typically be palpated during pelvic exam and is approximately 6.5 to 7 cm deep in the vagina on the lateral sidewall. Even when they are not prominent, the spines can typically be palpated directly after dissection of the anterior or posterior vaginal epithelium out to the sidewall.

The other important landmarks to palpate are the adductor longus tendon in the groin and the ischial

tubercle, as these help guide the surgeon for proper incision placement in the groin. For further detail, the reader is referred to a recently published review of pelvic anatomy by Barber.²²

Preventing Perioperative Complications

A protocol developed to prevent perioperative complications includes preoperative evaluation, antibiotic prophylaxis, prevention of thromboembolism, proper patient positioning, regional anesthesia, and adequate postoperative care.

Preoperative evaluation should begin with appropriate urogynecologic and medical evaluation. A detailed pelvic examination and urodynamic testing should be performed as indicated. Medical clearance should also be obtained from the patient's primary care physician.

Preoperative prophylactic antibiotics should be administered intravenously prior to pelvic surgery. Use of a cephalosporin or fluoroquinolone preoperatively is recommended, which is similar to the standard regimen for any vaginal surgery such as a hysterectomy or sling procedure.

Intraoperative and postoperative use of sequential compression devices (SCDs) may help reduce the risk of deep venous thrombosis. Heparin or enoxaparin, in addition to SCDs, should be used in patients at high risk for embolism because of previous thrombosis, prosthetics, or coagulation defects.

Patient positioning is crucial to avoid neuropathies involving the lower extremities or pelvis. A recent study has shown that flexion of the hip by 45° or more reduces the strain on the obturator nerve caused by abduction of the hip when the patient is placed in the traditional dorsal lithotomy position; this may also decrease the incidence of perioperative neuropathy.²³ Care should be taken, however, not to hyperflex the hips beyond 90° as this can cause hip pain following the surgery. The modified dorsal lithotomy position, with the buttocks level with the edge of the bed, is recommended for these procedures. Allen stirrups or other positionable stirrups are preferable to low or

TABLE 7

Tips to minimize mesh extrusions and dyspareunia

Mesh Extrusions	Dyspareunia
• Administer preoperative and postoperative estrogen	• Administer preoperative and postoperative estrogen
• Use a thick dissection plane	• Use a thick dissection plane
• Minimize the incision size	• Dissect all the way to the cuff, or beyond, so that the mesh lies flat
• Avoid trimming the vaginal epithelium	• Ensure that there is no tension on the graft or arms

“candy cane” stirrups because the former allow raising or lowering the legs as necessary for abdominal or perineal approaches. “Candy cane” stirrups also cause the hips to be too flexed, and this can make needle passage difficult. Positioning the patient before administering anesthesia may reduce the risk of complications in patients with previous lower-extremity surgery or back pain.

Spinal or epidural anesthesia with intravenous sedation is usually sufficient for reconstructive surgeries because these surgeries are performed predominantly via the vaginal or perineal route. For elderly patients, this anesthetic regimen is associated with a marked reduction in the postoperative cognitive dysfunction that this population may experience with general anesthesia.²⁴

Surgical Procedure

In contrast to traditional anterior or posterior colporrhaphy, the vaginal incisions should be kept as small as possible. The incision should be started distally (ie, at the bladder neck for Perigee and at the introitus or level of the hymenal ring for Apogee) and extended toward the apex of the vagina for approximately 2 to 4 cm. The incision should not be taken all the way up to the apex, as the dissection can be completed under the vaginal epithelium, and surgeons can tunnel their way up to the apex with blunt and/or sharp dissection and out to the sidewalls laterally. A Breisky-Navratil retractor placed under the vaginal epithelium is useful for exposure and dissection. This technique minimizes the size of the incision that needs to heal over the mesh, thereby reducing the risk of mesh exposure or extrusion through the incision (TABLE 7). Additionally, making a smaller incision helps the surgeon avoid cutting off too much vaginal epithelium (as will be discussed later).

If a vaginal hysterectomy is performed concomitantly, the hysterectomy should be completed first. The cuff can then be closed in a horizontal fashion and pushed back into the pelvis, and the subsequent incisions for the Perigee and Apogee should be made as

described earlier. Under no circumstances should the incision of the anterior or posterior wall be brought up to the cuff to make a “T” type incision: higher rates of mesh extrusion have been seen where these types of incisions meet.

The depth of the incision and subsequent dissection is also important. Deeper dissections and split-thickness dissections of the pubocervical or rectovaginal fasciae, especially when using synthetic mesh, reduce the likelihood of extrusion. Hydrodissection, using injections of saline or local anesthetic agents, facilitates dissection of the vaginal mucosa in the appropriate tissue plane.

When positioning the specially shaped needles to connect to the arms of the graft, it is important to avoid rotating the needles out past the introitus. This maneuver may be tempting to facilitate attaching the connectors on the arms to the needles, but could result in tearing the levator muscles, shortening the vaginal length, and, ultimately, a suboptimal outcome. Proper positioning is especially important with the Apogee needle, which must emerge close to the ischial spine, just through the levator muscles. The needle should be passed through the sidewall and advanced so that only 1 to 2 cm of the tip is exposed beyond the sidewall into the vagina. A Breisky-Navratil retractor can then be used both to isolate and expose the needle tip. A tonsil or other similar clamp should be used to grasp the connector and bring it up to the needle tip for permanent attachment (FIGURE 12). Once attached, the connector should be pushed back into the sidewall as the needle is drawn back out through the levators.

When passing the inferior or more apical Perigee needle, it is very important to drive the needle toward the ischial spine and to get it as close to the spine as possible before rotating the needle through the sidewall. The result will be a more apical suspension of the graft, again optimizing the repair. Care must be taken to minimize or eliminate all tension on the mesh while it is being positioned in the pelvis. In fact, it is preferable to leave the mesh a little loose. After adjusting the arms, the incision should be closed before removing the outer plastic sheaths from the arms so that the tension can be checked. This is achieved by pushing up on the arms at the lateral sulci vaginally (or on rectal exam for Apogee) to ensure that there is no tension on the arms. If tension is felt, the arms can be loosened by just pushing up on them. Once the surgeon is satisfied that the placement is tension free, the plastic sheaths can be removed.

Another technique to reduce the risk of mesh extrusion is to avoid or minimize trimming or excising the vaginal epithelium before closing the incision. This is a

step that most surgeons complete after traditional repair secondary to having redundant mucosa; however, when using a mesh, it is vital not to excise much epithelium. It has been shown that the tissue surrounding the mesh will shrink approximately 10% to 15%; therefore, the epithelium should be left very loose. If too much is excised or removed, the vaginal epithelium may retract, and mesh extrusion may occur through the incision.

The vaginal epithelium will usually contract into a normal anatomic shape within 2 to 4 weeks postoperatively. Vaginal packing should be used for 24 hours postoperatively to help reduce the risk of bleeding or hematoma formation. Intraoperative cystoscopy is recommended to ensure bladder integrity after the mesh has been positioned. Cystoscopy after each pass of the needle may also be of value during a surgeon's early learning stage.

Postoperative Care

Postoperative care should include early ambulation, pain control, and a voiding trial. A short course of postoperative antibiotics may be used, and vaginal estrogen should be started to reduce the risk of mesh extrusion or healing abnormalities.

Extrusion of the mesh at the incision is occasionally noted and can typically be managed quite easily. When the exposure is small and near the introitus, a course of topical estrogen cream should be used, and the exposed mesh may be trimmed in the physician's office. Typically, this is all that is necessary and results in no sequelae. Approximately 50% of mesh extrusions will heal on their own with vaginal estrogen cream alone. Antibiotics may be used at the physician's discretion.

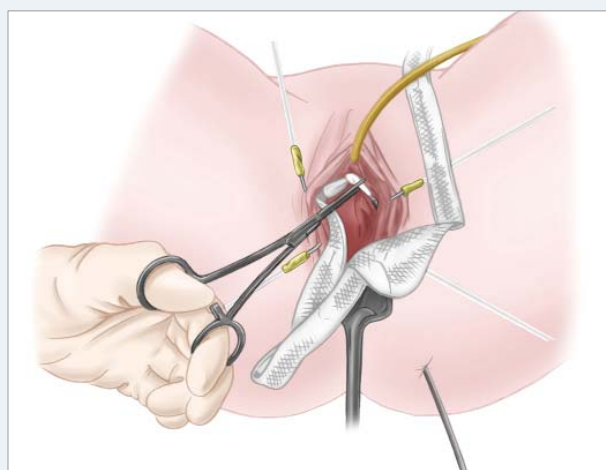
Larger exposures that require reapproximation of the mucosa are best treated in the operating room by excising the exposed mesh, excising and freshening the edges of the vaginal epithelium, and then closing the epithelium in a tension-free manner. Only the exposed mesh needs to be excised; the rest of the graft should be left intact. In a recent retrospective study of 299 cases, the preoperative use of estrogen was associated with a more than 2-fold decrease in the rate of extrusion.¹⁴ Biologic grafts were also associated with a lower extrusion rate; however, whether this finding was independent of other patient factors that led to selection of the biologic graft needs to be verified in a larger study.

Simultaneous Use of Perigee and Apogee

Perigee and Apogee are often used together to simultaneously repair multiple defects. When using them together, the anterior procedure may be performed first,

FIGURE 12

Apogee™ needle attached to connector at ischial spine

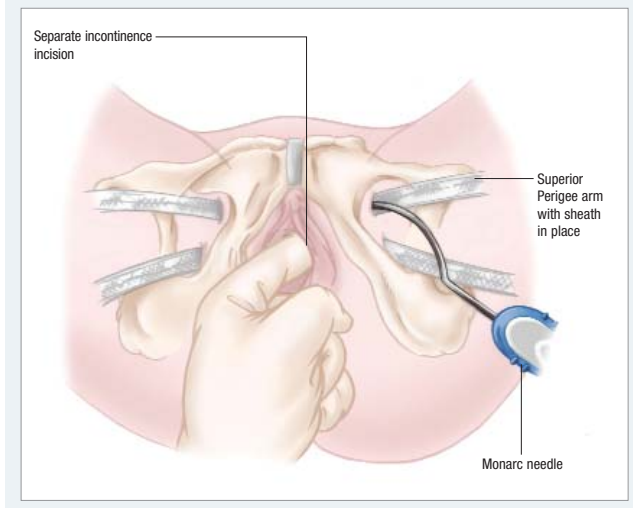


followed by the posterior procedure. If there is overlapping mesh at the apex, it is usually not necessary to suture the 2 ends together, as this could cause constriction of the vagina at the apex. My experience has shown that hysterectomy is not necessary for patients who still have a uterus unless uterine pathology is present. (Leaving the uterus in situ in such cases appears to be the preference among surgeons in Europe as well.) If the uterus is left in situ, the Perigee and Apogee tails can be connected directly to the pericervical ring and the uterus will be suspended with the procedures.

More than 50% of women who present with prolapse also have concomitant stress urinary incontinence (SUI). Repair of a cystocele can also on occasion unmask occult SUI. Urodynamics should be completed preoperatively with the prolapse reduced to check for SUI, and, if found, the patient will need a suburethral sling procedure at the time of Perigee and/or Apogee. In the past it was thought that an anterior wall graft might simultaneously treat SUI and cystocele; however, this has not proved to be the case. The Perigee procedure is designed for cystocele repair alone and, given the positioning of the graft, will not treat SUI. The Monarc™ Transobturator Subfascial Hammock or SPARC retro-pubic sling (American Medical Systems) may be placed at the same time as the Perigee for concomitant SUI repair. When using the Monarc with the Perigee, the Perigee procedure should be completed first, and then a separate incision should be made under the midurethral region for the Monarc sling. This will result in 2 separate incisions, with approximately 1 cm of intact tissue between the 2 incisions that will keep the Monarc sling

FIGURE 13

Monarc™ needle passage when used with Perigee™



in place under the midurethra and prevent it from sliding down onto the bladder neck.

The same superior Perigee groin incision may be used for the Monarc pass. The upper arms of the Perigee are typically left in place with the plastic sheaths still on them, and the Monarc needle is then passed through the superior portion of the incision without difficulty (FIGURE 13). Standard tension-free adjustment of the Monarc is completed, the plastic sheath is removed,

and the Monarc and Perigee arms are then cut off at the groin incision and closed with Steri-Strips™.

Minimizing Dyspareunia

Dyspareunia is a risk of any pelvic or vaginal surgery, and graft use in vaginal repairs has not demonstrated higher rates of dyspareunia than traditional repairs. When completing the Apogee and Perigee procedures, however, one can help minimize the risk of this outcome with a few simple steps. First, ensure that the tissue receives appropriate levels of estrogen both preoperatively and postoperatively, as this will help in healing, lubrication, and overall tissue health.

Second, the dissection plane should be thicker than that typically made during a traditional repair (ie, the surgeon should try to leave some fascia on the vaginal epithelium) so that the graft is lying deeper beneath the vaginal wall and is less likely to be palpated by the patient or her partner. In addition, the surgeon should ensure that there is no tension on the graft or the arms during placement. It is very important to take the dissection all the way up to or even beyond the cuff of the vagina to ensure that the graft lies flat and does not bunch up at the top of the vagina. Bunching can create scar tissue and/or discomfort with intercourse. If dyspareunia does occur, the physician should treat the tissues with adequate levels of estrogen, check for any bands of tension and release if necessary, and advise the patient to use pelvic floor physical therapy. ■

Conclusions

Vaginal prolapse is a prevalent condition that can significantly compromise patient quality of life. Traditional surgical treatments often have unacceptably high rates of recurrence and poor anatomic outcomes. Mesh or graft augmentation can provide greater stability than traditional repair and may decrease recurrence and the need for future procedures. Although augmentation has been historically associated with an increased risk of complications, recent clinical evidence demonstrates that augmentation generally is safe and effective, thanks largely to innovations in both mesh/graft materials and surgical placement techniques. The Perigee™ and Apogee™ repair systems are comprehensive kits that can offer surgeons flexibility and safety in mesh- and graft-augmented vaginal POP repair. These kits enable standardized, reproducible treatment with minimally invasive procedures.

Perigee™ Step-by-Step Procedure

Patient preparation

1. The patient is placed in modified dorsal lithotomy and prepared for surgery; an indwelling catheter and a weighted vaginal retractor may be placed if necessary.

Vaginal incision

2. A midline vaginal incision is made, distal to the bladder neck, over the most prominent part of the cystocele but several centimeters short of the apex. Blunt dissection is used to create a tunnel to the apex.
3. Blunt dissection or hydrodissection is used to dissect the bladder from the vaginal mucosa and to extend the dissection laterally to the medial edge of the inferior pubic ramus.

Marking and incision of needle entry points

4. The edge of the ischiopubic ramus is palpated beginning at the superior edge of the vaginal incision in a cephalad direction toward the level of the clitoris, denoting where the adductor longus tendon inserts into the pubic ramus. The site of the superior skin incision is marked at the lateral edge of the bone at the level of the clitoris. The same maneuver is repeated on the patient's contralateral side.
5. Next, the edge of the inferior pubic ramus is palpated until it ends at the bottom of the obturator foramen. This site is marked for inferior skin incisions. The inferior incisions are approximately 3 cm below and 2 cm lateral to the superior marks.
6. Vertical stab incisions are made over these marks.

Insertion of the helical superior needles through the obturator foramen

7. The right superior needle, identified by its pink handle and the arrow pointing to the surgeon's right, is inserted first. The needle tip is pointed perpendicular to the skin and in the superior incision while the needle shaft and handle are positioned at a 45° angle to the patient's vertical axis.
8. The right superior needle is advanced through the obturator muscle and membrane using gentle pressure exerted by the surgeon's left thumb placed on the outside curve of the needle to control needle movement.
9. The handle is rotated so that the needle tip and curve move around the posterior surface of the ischiopubic ramus toward the vaginal incision.
10. The needle tip is palpated with the index finger as it moves around the pubic ramus.
11. The needle tip is then guided toward the vaginal incision until the needle tip extends through the incision.

Insertion of the inferior needles through the obturator foramen

12. The right inferior needle, identified by its gray handles and arrow pointing to the surgeon's right, is inserted next. The needle is positioned with the needle tip perpendicular to the skin and in the inferior incision while the needle and shaft are positioned parallel to the patient's vertical axis and close to the patient's body.
13. The needle is advanced through the obturator muscle and membrane, with gentle pressure exerted by the thumb of the left hand placed on the outside curve of the needle.

14. The needle handle is rotated, moving the needle tip and curve toward the proximal end of the vaginal incision (toward the vaginal apex).
15. The needle tip is palpated with the index finger of the left hand as it moves through the proximal end of the vaginal incision.
16. The right inferior connector is attached to the needle tip, and the needle tip is rotated back through the skin incision, pulling the mesh arms and insertion sheath into position.
17. The needle passage and mesh connection are repeated on the patient's contralateral side.
18. The connectors are removed by cutting below the marks on the sheath.
19. Cystoscopy may be performed at this stage to check the integrity of the bladder.

Mesh attachment and positioning

20. The mesh is oriented so that the tail end is pointing down toward the operating table.
21. The right superior pink connector is attached to the needle after ensuring that the arms of the mesh are not twisted. The attachment of the connector to the needle is permanent.
22. The needle is then rotated back through the skin incision, pulling the connector and associated mesh insertion sheath and self-fixating arm into position.
23. The procedure is repeated on the patient's contralateral side.
24. The mesh insertion sheath is cut below the blue mark to remove the connector. This allows the insertion sheath to slide freely relative to the mesh.

Positioning of the mesh

25. After removing all vaginal retractors, the mesh should be positioned to lie flat, with the superior edge below the bladder neck without tension.
26. The tail of the graft should be positioned toward the vaginal apex and trimmed according to the size of the bladder bulge.
27. The graft may be tightened under the bladder bulge by pulling on the sheath-enclosed self-fixating arms of the mesh.
28. The graft may be loosened by placing a surgical instrument between the graft and the vaginal wall and pulling down with gentle traction until proper adjustment is achieved.
29. Once all adjustment is done, the plastic sheaths covering each of the arms are removed and discarded.

Closing all incisions

30. The self-fixating mesh appendages are trimmed to the level of the skin, and the skin incisions are closed.
31. The vaginal incision is closed next.
32. Postoperative care includes prophylactic antibiotics, bladder catheter, if needed, and vaginal packing as well as early ambulation, pain control, vaginal estrogen, and a voiding trial.
33. Spontaneous voiding must be confirmed before the patient can be discharged.

Apogee™ Step-by-Step Procedure

Patient preparation

1. The patient is placed in modified dorsal lithotomy and prepared for surgery; an indwelling catheter is placed if necessary.

Vaginal incision

2. After marking the apex and lateral sulci, a midline incision is made in the posterior vaginal wall over the most prominent part of the rectocele bulge, 2 to 4 cm in length and no less than 2 cm distal to the vaginal apex.
3. The vaginal mucosa is dissected from the rectovaginal fascia using blunt dissection or hydrodissection. Split-thickness dissection of the rectovaginal fascia may also be employed.

Marking and incision of needle entry points

4. Two small stab incisions are made, 1 on each side of the rectum, approximately 3 cm lateral and 3 cm posterior to the anus.

Insertion of the curved needles through the ischiorectal fossa

5. The curved Apogee needle is then positioned with the needle tip perpendicular to the skin and the handle tip, held between the thumb and forefinger, pointing upward in a 12 o'clock position.
6. The needle is then advanced at a slightly upward and lateral angle through the buttock until a pop is felt, signifying needle entry into the ischiorectal fossa.
7. The needle is passed laterally and parallel to the rectum toward the ischial spine.
8. When the needle tip can be palpated in front of the ischial spine, the tip is turned medially toward the vaginal vault so that it penetrates the levator muscle.
9. A rectal exam is conducted to verify rectal integrity.
10. The same steps are repeated on the patient's contralateral side.

Positioning of the mesh

11. The mesh is positioned so that the shorter tail lies toward the apex.
12. The connector is attached to the respective needle, and the needles are withdrawn through the skin incision. It may be necessary to push the connector through the levator muscles with the thumb of the hand that is positioned intravaginally.
13. The connector is removed by cutting the sheath just below the connector, which allows the sheath and arms of the mesh to move freely from the central portion.
14. The mesh is attached to the apex of the vaginal wall with 2 or more sutures.
15. Elevate the apex digitally while pulling on the mesh arms. Do not pull on mesh arms alone as it may put too much tension on the mesh.
16. The mesh should lie flat and should not extend beyond the perineum. Sutures may be used to attach the longer tail of the mesh to the levator muscle laterally.
17. Once all adjustments are finished, the plastic sheaths covering each of the arms are removed and discarded.

Closing all incisions

18. The arm mesh is trimmed at the level of the skin incision, and the incisions are closed.
19. The vaginal incision is closed.
20. Postoperative care includes prophylactic antibiotics, bladder catheter, if needed, and vaginal packing as well as early ambulation, pain control, vaginal estrogen, and a voiding trial.
21. Spontaneous voiding must be confirmed before the patient can be discharged.

References

1. Beer M, Kuhn A. Surgical techniques for vault prolapse: a review of the literature. *Eur J Obstet Gynecol Reprod Biol.* 2005;119:144-155.
2. Thakar R, Stanton S. Management of genital prolapse. *BMJ.* 2002;324:1258-1262.
3. Mouritsen L, Larsen JP. Symptoms, bother and POPQ in women referred with pelvic organ prolapse. *Int Urogynecol J Pelvic Floor Dysfunct.* 2003;14:122-127.
4. Olsen AL, Smith VJ, Bergstrom JO, Colling JC, Clark AL. Epidemiology of surgically managed pelvic organ prolapse and urinary incontinence. *Obstet Gynecol.* 1997;89:501-506.
5. Bump RC, Mattiasson A, Bo K, et al. The standardization of terminology of female pelvic organ prolapse and pelvic floor dysfunction. *Am J Obstet Gynecol.* 1996;175:10-17.
6. Mouritsen L. Classification and evaluation of prolapse. *Best Pract Res Clin Obstet Gynaecol.* 2005;19:895-911.
7. Weber AM, Walters MD, Piedmonte MR, Ballard LA. Anterior colporrhaphy: a randomized trial of three surgical techniques. *Am J Obstet Gynecol.* 2001;185:1299-1304.
8. Sand PK, Koduri S, Lobel RW, et al. Prospective randomized trial of polyglactin 910 mesh to prevent recurrence of cystoceles and rectocele. *Am J Obstet Gynecol.* 2001;184:1357-1362.
9. Kohli N, Sze EH, Roat TW, Karam MM. Incidence of recurrent cystocele after anterior colporrhaphy with and without concomitant transvaginal needle suspension. *Am J Obstet Gynecol.* 1996;175:1476-1480.
10. Kohli N, Goldberg R, Maccaroni J. Augmenting pelvic floor repairs. *OBG Management.* 2006;18(suppl):S1-S8.
11. Biller DH, Davila GW. Vaginal vault prolapse: identification and surgical options. *Cleve Clin J Med.* 2005;72(suppl 4):S12-S19.
12. Maher C, Baessler K. Surgical management of anterior vaginal wall prolapse: an evidencebased literature review. *Int Urogynecol J Pelvic Floor Dysfunct.* 2006;17:195-201.
13. Walters MD, Paraiso MFR. Anterior vaginal wall prolapse: innovative surgical approaches. *Cleve Clin J Med.* 2005;72(suppl 4):S20-S27.
14. Data on file. Protocol #MES052. American Medical Systems, Minnetonka, Minn.
15. Francis SL. Posterior IUS and other apical prolapse surgeries. *OBG Management.* 2004;16(suppl):S6-S11.
16. Rane AM, Naidu AK, Barry CL, Nyok LY, Corstiaans AC. A novel transobturator system for the repair of anterior vaginal wall prolapse: a pilot study [abstract]. *Int Urogynecol J.* 2005;16(suppl 2):S104. Abstract 319.
17. Davila GW, Beyer R, Moore R, Del Rio S. Restoration of vaginal apical and posterior wall support with the Apogee system [abstract]. *Int Urogynecol J.* 2005;16(suppl 2):S118. Abstract 362.
18. Davila G, Flaherty J, Lukban J, Beyer R, Patel M, Moore R. Retrospective analysis of efficacy and safety of Perigee and Apogee in patients undergoing repair for pelvic organ prolapse. Poster accepted for: 27th Annual AUGS Scientific Meeting 2006; October 19-21, 2006; Palm Springs, Calif.
19. Gandhi S, Kubba LM, Abramov Y, et al. Histopathologic changes of porcine dermis xenografts for transvaginal suburethral slings. *Am J Obstet Gynecol.* 2005;192:1643-1648.
20. Davila GW. Optimizing pelvic surgery outcomes. *Cleve Clin J Med.* 2005;72(suppl 4):S28-S32.
21. Data on file. Internal test report 3135. American Medical Systems, Minnetonka, Minn.
22. Barber MD. Contemporary views on female pelvic anatomy. *Cleve Clin J Med.* 2005;72(suppl 4):S3-S11.
23. Litwiller JP, Wells RE Jr, Halliwell JR, Carmichael SW, Warner MA. Effect of lithotomy positions on strain of the obturator and lateral femoral cutaneous nerves. *Clin Anat.* 2004;17:45-49.
24. Rasmussen LS, Johnson T, Kuipers HM, et al. Does anaesthesia cause postoperative cognitive dysfunction? A randomised study of regional versus general anaesthesia in 438 elderly patients. *Acta Anaesthesiol Scand.* 2003;47:260-266.